



PATIENT

Calvin Peel

SPECIES

Canine

BREED

English Bulldog

SEX

Male Neutered

AGE

7.7.11

WEIGHT

56.2lbs

PRESENTING CLINICAL SIGNS

History: 3/15/22 presented for retching, gagging intermittently but with increasing frequency. New 3/6 murmur was detected 10/2021.

-Pertinent abnormal PE/Chem/CBC/UA Results: Chest rads 3/15/22- Sig cardiomegaly. VHS 14+. Enlarged pulmonary vessels. Difficulty interpreting the lungs.

-Current medications: Single dose Lasix 2.2mg/kg 3/25 pm. No additional meds for heart. Clavacillin 375mg BID and Tussigon 5mg 1-2 TID. Gabapentin 500mg prior to scan.

-Sedation used: Not required to complete full diagnostic ultrasound.

-Pertinent previous ultrasound results: No previous.

-STAT: Not requested

-Imaging performed by: Andi Parkinson, RDMS

ECHOCARDIOGRAM FINDINGS

2D, m-mode, color flow and doppler imaging is available. Large uniform echogenicity mass associated with the aortic root; 6.5 x 5.0cm in best viewed cross section. The mass is well encapsulated and near the bifurcation overlying the aorta/LA. No obstruction to blood flow is seen or obvious imposition on cardiac chambers. There is moderate eccentric mitral regurgitation, a thickened mitral valve without obvious prolapse. LV dimension is normal with adequate function. Left atrium is moderately dilated, although the mass obscures standard measurement. Mildly thickened TV with mild TR. Normal right heart chamber dimensions. The pulmonic and aortic valves are normal in appearance. Normal LVOT and RVOT velocity. No AI or PI identified. No pericardial or pleural effusion.

INTERPRETED BY

Maggie Machen Lamy,
DVM, DACVIM
(Cardiology)

HOSPITAL NAME

Eastern Animal
Hospital

REFERRING VET

Dr. Warner-Jones

INVOICE

23150

DATE

3.17.22

CARDIAC CHART

CANINE CARDIAC PARAMETERS	MR VMAX (m/s)	TR VMAX (m/s)	LA/AO (Boon method)	LA/AO (Heart Base; Swe)	FS (%)	EF (%)	EPSS (cm)
NORMAL PARAMETER	4.5-5.5	<2.7	1.3	<1.6	28-40	40-100	<0.6
PATIENT	5.1	NM	NM	1.75	35	65	NM
CANINE CARDIAC PARAMETERS	HR (BPM)	AV VMAX (m/s)	PV MAX (m/s)	BODY WEIGHT (kg)	LA 2D short axis Base view (cm)	LVIDd Avg; 2D and m-mode short axis (cm)	LVIDs Avg; 2D and m-mode short axis (cm)
NORMAL PARAMETER	50-100	0.7-1.7	0.7-1.6	BELOW	BELOW	BELOW	BELOW
PATIENT	150	1.6	1.0	25.5	3.7	4.5	2.9
*Normal chamber parameters expressed as a mean value (SD)				3	1.27 (5.3)	2.46 (2.46)	1.36 (5.5)
BODY WEIGHT DEPENDENT PARAMETERS							
*Note: All measurements based upon multi-modal images and methods. An average value is reported.				5	1.40 (4.5)	2.74 (5.2)	1.60 (4.7)
				10	1.50 (3.8)	3.27 (3.5)	2.06 (3.1)
				15	1.83 (2.0)	3.71 (2.4)	2.43 (2.1)
				20	2.02 (1.9)	4.14 (2.2)	2.80 (2.0)
				25	2.18 (2.4)	4.48 (2.9)	3.10 (2.5)
				30	2.33 (3.3)	4.83 (3.9)	3.39 (3.4)
				35	2.48 (4.3)	5.17 (5.0)	3.69 (4.5)
				40	2.62 (5.2)	5.48 (6.1)	3.96 (5.4)
				50	2.88 (7.1)	6.07 (8.3)	4.46 (7.4)

Adapted from June Boon, Veterinary Echocardiography, 1998
Rishniw M and Hollis NE, J Vet Intern Med 2000; 14:429-435
Hansson et al, Vet Rad and Ultrasound 2002
Bonagura et al. Echocardiography: principles of interpretation, Vet Clin North Am 15:1177, 1995

INTERPRETATION OF THE FINDINGS & FURTHER RECOMMENDATIONS

The murmur is due to chronic degenerative valve disease causing moderate mitral and mild tricuspid regurgitation. Moderate left atrial enlargement indicates the current risk for complication is low but may progress in the future. No obvious pulmonary hypertension is identified with normal right heart dimensions. No additional structural issues are identified.

Of equal importance, there is suspect cardiac neoplasia associated with the heart base. The most likely tumor type given this location and the breed is a chemodectoma, however other more malignant differentials cannot be ruled out. Chemodectomas are often incidental findings as is suspected to be the case here, only causing clinical signs if blood flow is obstructed, pericardial effusion occurs, or a metastatic lesion causing systemic issues. It is difficult to definitively evaluate the mass peripherally (i.e., cannot rule out peripheral obstruction of flow through distal PA's) and a CT may be helpful to screen for true extent.

The prognosis with cardiac chemodectomas is fair. The limiting factor is often hemorrhage into the pericardium, impingement of cardiac blood flow secondary to tumor growth, or metastasis to the thorax or abdomen. Chemotherapy and/or radiation therapy can also be discussed with an Oncologist.

Given these findings, the mass may certainly be contributing to a cough symptom. The cough may progress as the tumor grows, particularly should chamber imposition develop. The right heart is not enlarged which likely suggests compression is minimal at this time. Should the tumor increase in dimension and lead to congestion, this is most commonly right-sided (ascites/pleural effusion) with increasing pulmonary pressures and syncope with exertion. Monitoring is advised.

Continued cough management is recommended using more aggressive Hydrocodone, a course of Baytril, a trial of Theophylline, etc. No obvious indication for Lasix prior to congestive signs.

Given the totality of the findings, recommend Pimobendan in this case as below. Monitor for development of a cough, labored breathing, exercise intolerance or collapse episodes.

Omega fatty acid supplementation and mild salt restriction may be of some long-term benefit. Monitor for development of a cough, labored breathing, exercise intolerance or collapse episodes. Prognosis is guarded long-term.

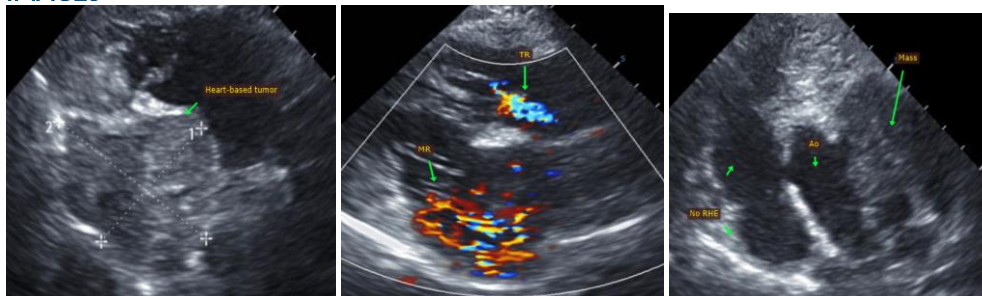
Anesthetic risk is considered moderately elevated if needed. Cardiac protective drug choices (opioid/benzodiazepine premedication, propofol or alfaxalone induction, isoflurane gas) are recommended. Pre-oxygenate for 5-10 minutes prior to induction. Monitor for arrhythmias, hypotension, and hypoxia both intra and post-operatively and intervene as necessary. Mild IV fluid restriction is recommended to avoid fluid overload. Avoid heart rate stimulating drugs such as atropine unless clinically indicated.

PLAN

Institute Pimobendan 0.3mg/kg PO q12h. Consider cough management, utilizing Hydrocodone, etc. as discussed. Consider further evaluation of tumor extent through thoracic CT as discussed. Oncology/IM consultation if desired.

Recheck tumor size via echocardiography in 4-6 months, sooner if clinical signs arise.

IMAGES



The information and recommendations provided are based on the images presented by the referring veterinarian. No evaluation can be communicated regarding pathology that was not visible in the image/video clips provided.

Thank you for this referral. This report was generated using transcription software, and minor dictation errors may be present. If the clinical or image interpretation does not parallel your findings or if I can be of any further assistance, please contact me.

Maggie Machen Lamy, DVM
Diplomate of the American College of Veterinary Internal Medicine (Cardiology)
info@sonopath.com